

Applanation epitheliopathy

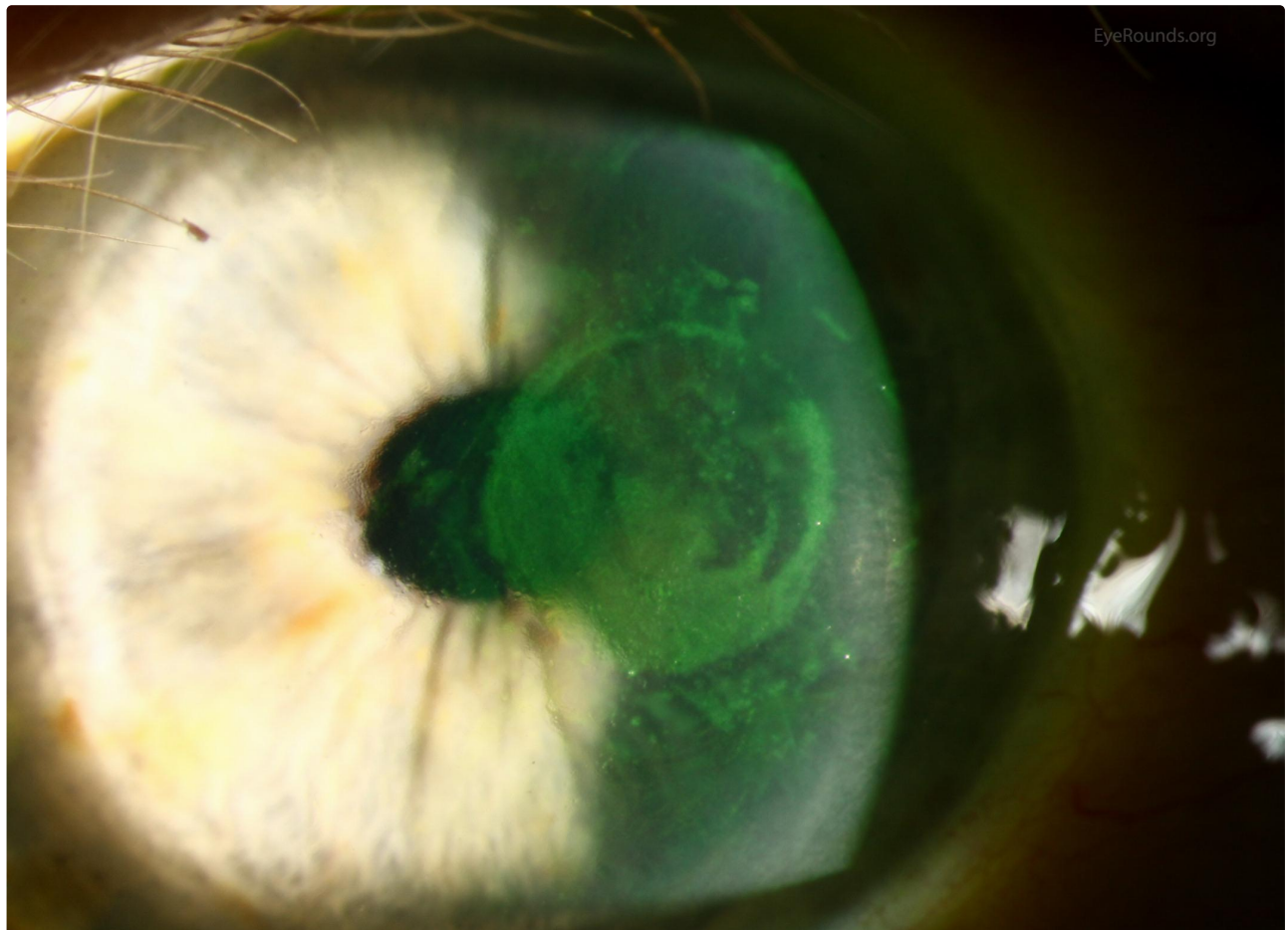
Category(ies): Cornea, Glaucoma, Iris

Contributor: [Jesse Vislisel, MD](#) and [Wallace L.M. Alward, MD](#)

Photographer: Stefani Karakas, CRA



Applanation tonometry is the gold standard for intraocular pressure assessment. During this technique a circular Goldmann applanation tip contacts the surface of the cornea. Epithelial disruption may occur if care is not taken during applanation, leading to a circle of positive fluorescein staining as seen in this photograph.



[Enlarge](#)

[Download](#)

Image Permissions:



Ophthalmic Atlas Images by [EyeRounds.org](#), [The University of Iowa](#) are licensed under a [Creative Commons Attribution-NonCommercial-NoDerivs 3.0 Unported License](#).

Address

University of Iowa
Roy J. and Lucille A. Carver College
of Medicine
Department of Ophthalmology and
Visual Sciences
200 Hawkins Drive
Iowa City, IA 52242

[Support Us](#)

Legal

Copyright © 2019 The University of
Iowa. All Rights Reserved
[Report an issue with this page](#)
[Web Privacy Policy](#) |
[Nondiscrimination Statement](#)

Related Links

[Cataract Surgery for Greenhorns](#)
[EyeTransillumination](#)
[Gonioscopy.org](#)
[Iowa Glaucoma Curriculum](#)
[Iowa Wet Lab](#)
[Patient Information](#)
[Stone Rounds](#)
[The Best Hits Bookshelf](#)

EyeRounds Social Media

Follow



[Receive notification of new cases,
sign up here](#)
[Contact Us](#)
[Submit a Suggestion](#)